



International Journal of Pharmacy & Therapeutics

Journal homepage: www.ijptjournal.com

IJPT

STUDY OF THE TERMINATION OF SCIATIC NERVE IN POPLITEAL FOSSA IN 50 CADAVERS

Sharadkumar Pralhad Sawant*

Professor and Head, Department of Anatomy, K.J.Somaiya Medical College, Somaiya Ayurvihar, Eastern Express Highway, Sion, Mumbai-400 022, Maharashtra, India.

ABSTRACT

Aim to study the termination of sciatic nerve in popliteal fossa in 50 cadavers. 100 lower limbs of 50 donated embalmed cadavers (45 males & 5 females) of age group ranging from 70 to 80 years were dissected in the department of Anatomy at K. J. Somaiya Medical College, Sion, Mumbai, INDIA. The variant termination of sciatic nerve in popliteal fossa were observed in 2 specimens. The musculo - vascular pattern in the back of thigh and leg was also studied. The photographs of the trifurcation of the sciatic nerve were taken for proper documentation and for ready reference. The sciatic nerve is the thickest nerve in the body. It leaves the pelvis via the greater sciatic foramen below piriformis and descends between the greater trochanter and ischial tuberosity, along the back of the thigh, dividing into the tibial and common peroneal (fibular) nerves at a varying level proximal to the knee. In the present study, we observed an unusual trifurcation of the sciatic nerve on the back of the left thigh in 2 specimens. The sciatic nerve terminates in the middle of the popliteal fossa into the tibial, the common peroneal (fibular) and the sural nerves. The photographs of the trifurcation of the sciatic nerve were taken for proper documentation and for ready reference. The trifurcation of the sciatic nerve is very rare. The knowledge of low level of termination of sciatic nerve is important for clinicians and surgeons. Clinically, the sural nerve is widely used for both diagnostic (biopsy and nerve conduction velocity studies) and therapeutic purposes (nerve grafting). Thus, a detailed knowledge of the anatomy of the sural nerve and its contributing nerves are important in carrying out these and other procedures.

Key Words:- Sciatic Nerve, Trifurcation, Tibial Nerve, Common Peroneal, Lateral Sural Cutaneous Nerve, Popliteal Fossa, Sural Nerve.

INTRODUCTION

The sciatic nerve (also known as the ischiadic nerve and the ischiatic nerve) is 2 cm wide at its origin and is the thickest nerve in the body. It leaves the pelvis via the greater sciatic foramen below piriformis and descends between the greater trochanter and ischial tuberosity, along the back of the thigh, dividing into the tibial and common peroneal (fibular) nerves at a varying level proximal to the knee.

Superiorly it lies deep to the gluteus maximus, resting first on the posterior ischial surface with the nerve to the quadratus femoris lying between them. It then crosses posterior to the obturator internus, the gemelli and quadratus femoris, separated by the latter from obturator externus and the hip joint. It is accompanied medially by the posterior femoral cutaneous nerve and the inferior gluteal artery. More distally it lies behind adductor magnus and is crossed posteriorly by the long head of biceps femoris. It corresponds to a line drawn from just medial to the midpoint between the ischial tuberosity and greater trochanter to the apex of the popliteal fossa.

Corresponding Author

Sharadkumar Pralhad Sawant

Email: - drspsawant@gmail.com

Articular branches arise proximally to supply the hip joint through its posterior capsule, these are sometimes derived directly from the sacral plexus. Muscular branches are distributed to biceps femoris, semitendinosus, semimembranosus and the ischial part of adductor magnus. The point of division of the sciatic nerve into the tibial and the common peroneal nerve is very variable. The common site is at the junction of the middle and lower thirds of the thigh, near the apex of the popliteal fossa. The division may occur at any level above this, through rarely below it. It is not uncommon for the major components to leave the sacral plexus separately, in which case the common peroneal component usually passes through piriformis at the greater sciatic notch while the tibial component passes below the muscle (Standing, 2008). The sciatic nerve supplies the knee flexors and all the muscles below the knee, so that a complete palsy of the sciatic nerve results in a flail foot and severe difficulty in walking. This is rare and usually related to trauma. The nerve is vulnerable in posterior dislocation of the hip. As it leaves the pelvis it passes either behind piriformis or sometimes through the muscle and at that point it may become entrapped (the piriformis syndrome; this is a common anatomical variant but an extremely rare entrapment neuropathy). External compression over the buttock (e.g. in patients who lie immobile on a hard surface for a considerable length of time) can injure the nerve. Sadly the most common cause of serious sciatic nerve injury (and consequent major medicolegal claims) is iatrogenic. It may be damaged in misplaced therapeutic injections into gluteus maximus. The safe zone for deep intramuscular injections here is the upper outer quadrant of the buttock. Perhaps safer still is to inject into the quadriceps, through this can produce problems of its own, e.g. haemorrhage, leading to contracture of the muscle, which limits knee motion. Sciatic nerve palsy occurs after total hip replacement or similar surgery in 1% of cases. This can be due to sharp injury burning from bone cement, traction from instruments, manipulation of the hip, inadvertent lengthening of the femur, or haematoma surrounding the nerve or within its soft tissue coverings. Haematoma is characterized by the development of severe pain in the immediate post-operative period. Early surgical exploration and evacuation of haematoma can reverse the nerve lesion. Unfortunately the other causes may not be influenced. The majority are temporary. Complete sciatic nerve palsy is very rare. For some reason, possibly anatomical, the common peroneal part is more usually affected alone. The patient has a foot drop and a high stepping gait. The sciatic nerve bifurcates into two major divisions (tibial and common peroneal), most commonly at the lower part of the posterior compartment of the thigh

(Yuen and So, 1999). Several authors have reported variations on its division into the tibial and common peroneal nerve from the sacral plexus to the lower part of the popliteal space (Paval and Nayak, 2006). These anatomical variations may contribute to piriformis syndrome, sciatica, coccygodynia and muscle atrophy (Babinski et al., 2003). This should be taken into account by clinicians who are planning interventions around the sciatic nerve and its division in the lower extremity. Higher level of the sciatic nerve division is a relatively frequent phenomenon. The sural nerve (short saphenous nerve), is a sensory nerve formed by the union of the medial sural cutaneous with the peroneal anastomotic branch of the lateral sural cutaneous nerve, passes downward near the lateral margin of the tendo calcaneus, lying close to the small saphenous vein, to the interval between the lateral malleolus and the calcaneus. It runs forward below the lateral malleolus, and is continued as the lateral dorsal cutaneous nerve along the lateral side of the foot and little toe (via a dorsal digital nerve), communicating on the dorsum of the foot with the intermediate dorsal cutaneous nerve, a branch of the superficial peroneal. In the leg, its branches communicate with those of the collateral branches of the common tibial, and common fibular nerve.

MATERIALS AND METHODS

100 lower limbs of 50 donated embalmed cadavers (45 males & 5 females) of age group ranging from 70 to 80 years were dissected in the department of Anatomy at K. J. Somaiya Medical College, Sion, Mumbai, INDIA. The variant the termination of sciatic nerve in popliteal fossa were observed in 2 specimens. The musculo - vascular pattern in the back of thigh and leg was also studied. The photographs of the trifurcation of the sciatic nerve were taken for proper documentation and for ready reference.

Observations

The sciatic nerve is the thickest nerve in the body. It leaves the pelvis via the greater sciatic foramen below piriformis and descends between the greater trochanter and ischial tuberosity, along the back of the thigh, dividing into the tibial and common peroneal (fibular) nerves at a varying level proximal to the knee. In the present study, we observed an unusual trifurcation of the sciatic nerve on the back of the left thigh in 2 specimens. The sciatic nerve terminates in the middle of the popliteal fossa in to the tibial, the common peroneal (fibular) and the sural nerves. The photographs of the trifurcation of the sciatic nerve were taken for proper documentation and for ready reference.

DISCUSSION

During embryological development at the base of the limb bud, the nerves contributing to the lower limb forms two plexuses (lumbar and sacral) (Demiryurek et al., 2012). Later, as the elements from each of these plexuses grow out into the limb, they are subdivided into dorsal and ventral components, for the dorsal and ventral musculatures. The sciatic nerve is formed when the large dorsal component of the sacral plexus (common fibular nerve) and the ventral component (tibial nerve) moves downward close together.

A number of variations in the course and distribution of the sciatic nerve have been reported. Bifurcation into its two major divisions (common peroneal and tibial) may occur anywhere between the sacral plexus and the lower part of the thigh. The two terminal branches of the sciatic may arise directly from the sacral plexus (Bergman et al., 1988). Pokorný et al, Ugrenović et al, Gabrielli et al, Saleh et al and Güvençer et al studied the different level of division of the sciatic nerve (Pokorný et al., 2006). When the sciatic nerve divides in the pelvis, the common peroneal nerve usually pierces the piriformis muscle. The common peroneal nerve passes either through the piriformis or above the piriformis (Ugrenovic et al., 2005). The entire sciatic nerve may pass through the piriformis causing the sciatica (Chen, 1994). The tibial nerve passing deep and common peroneal nerve passing superficial to the superior gemellus has been found in literature. The trifurcation of sciatic nerve into tibial, common peroneal and lateral cutaneous nerve of calf has been observed (Nayak, 2008) but the trifurcation of sciatic nerve into tibial, common peroneal and sural nerves is not documented in literature. Normally the sural nerve is formed by medial sural cutaneous nerve arising from the tibial nerve and lateral sural cutaneous nerve from the common peroneal nerve. The knowledge of these variations is important because the sural nerve is the most frequently used sensory nerve in nerve transplantation.

Reports on variations and surgical application of the variations of sural and peroneal communicating nerve are available in literature (Mahakkanukrauh and Chomsung, 2002; Benjamim et al., 1995). The present case of trifurcation of the sciatic nerve is important to surgeons who do the popliteal block for leg surgery, because high divisions of sciatic nerve may lead to failure of popliteal block anesthesia (Vloka, 2001). The thick sural nerve in this case is ideal for nerve grafts. Since the division of sciatic nerve is very low, its branches may interfere in knee surgery. The knowledge of the trifurcation of the sciatic nerve seen in the present case extremely important to the surgeons dealing with popliteal aneurysms. Although entrapment of the sural nerve is a rare condition, the resultant pain can be debilitating for patients. A thorough knowledge of the trajectory of the nerve is essential for establishing a diagnosis, as well as for treatment.

Clinical significance

The trifurcation of the sciatic nerve is important to the surgeons who perform the popliteal block for leg surgery, because high divisions of sciatic nerve may lead to failure of popliteal block anesthesia. The sural nerve subserves a purely sensory function, and therefore its removal results in only a relatively trivial deficit. For this reason, it is often used for nerve biopsy, as well as the donor nerve when a nerve graft is performed. The sural nerve is the most frequently used sensory nerve in nerve transplantations. It is either transplanted alone or together with the other elements of the neurovascular stalk within the superficial sural flap.

Clinically, the sural nerve is widely used for both diagnostic (biopsy and nerve conduction velocity studies) and therapeutic purposes (nerve grafting). Thus, a detailed knowledge of the anatomy of the sural nerve and its contributing nerves are important in carrying out these and other procedures.

Figure 1. Showing the photographic presentation of the sciatic nerve terminated in the middle of the popliteal fossa by giving three branches. The three branches given were the tibial, common peroneal and sural nerves.

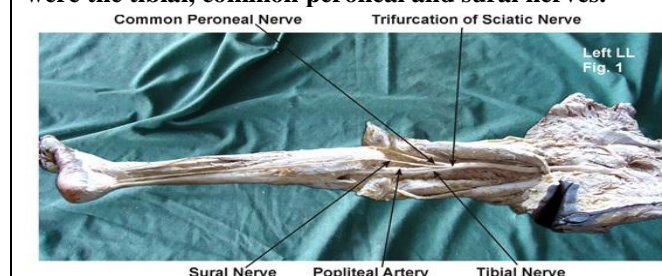
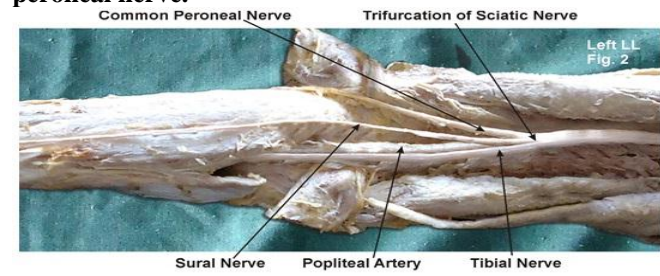


Figure 2. Showing the photographic presentation of common peroneal nerve reduced in size due to the sural nerve, which was almost as thick as the common peroneal nerve.



CONCLUSION

The existence of such variations should be kept in mind by the surgeons dealing with popliteal aneurysms, by the orthopaedicians dealing with fracture of the femur, the radiologists while doing radiodiagnostic procedures e.g. CT scan, MRI of the thigh, by anaesthetists performing pain management and also by the physiotherapists.

ACKNOWLEDGEMENT

The authors wish to convey his sincere thanks to our Dean Dr. Geeta Niyogi Madam for her valuable help, support and inspiration. I am also thankful to Mr. M. Murugan. Author also acknowledge the immense help received from the scholars whose articles are cited and

included in references of this manuscript. The author is also grateful to authors / editors / publishers of all those articles, journals and books from where the literature for this article has been reviewed and discussed.

Competing Interests

The author declares that he has no competing interest.

Authors' contributions

SPS draft the manuscript, performed the literature review & obtained the photograph for the study.

REFERENCES

- Babinski MA, Machado FA, Costa WS. A rare variation in the high division of the sciatic nerve surrounding the superior gemellus muscle. *Eur J Morphol*, 41, 2003, 41-2.
- Benjamim AC, Tuma Junior P, Grillo MA, Ferreira MC. Surgical anatomy of the sural nerve. *Rev Hosp Clin Fac Med Sao Paulo*, 50, 1995, 25-29.
- Bergman RA, Afifi AK, Miyauchi R. Compendium of human anatomical variations. Baltimore, Urban and Schwarzenberg. 1988, 146.
- Chen WS. Bipartite piriformis muscle, an unusual cause of sciatic nerve entrapment. *Pain*, 58, 1994, 269-272.
- Demiryurek D, Bayramoglu A, Erbil M, Aldur MM, Mustafa ES. Bilateral divided piriformis muscle together with the high division of the sciatic nerve. *Gazi Med J*, 13, 2002, 41-4.
- Mahakkanukrauh P, Chomsung R. Anatomical variations of the sural nerve. *Clin Anat*, 15, 2002, 263-266.
- Nayak S. An unusual case of trifurcation of the sciatic nerve. *Neuroanatomy*, 5, 2008, 6-7.
- Paval J, Nayak S. A case of bilateral high division of sciatic nerve with a variant inferior gluteal nerve. *Neuroanatomy*, 5, 2006, 33-4.
- Pokorný D, Jahoda D, Veigl D, Pinskerová V, Sosna A. Topographic variations of the relationship of the sciatic nerve and the piriformis muscle and its relevance to palsy after total hip arthroplasty. *Surg Radiol Anat*, 28, 2006, 88-91.
- Standring S. Gray's Anatomy, 40th Ed, London, Elsevier Churchill Livingstone 2008, 1456.
- Ugrenovic S, Jovanovic I, Krstic V, Stojanovic V, Vasovic L, Antic S, Pavlovic S. The level of the sciatic nerve division and its relations to the piriform muscle. *Vojnosanit Pregl*, 62, 2005, 45-49.
- Vloka JD, Hadzić A, April E, Thys DM. The division of the sciatic nerve in the popliteal fossa, anatomical implications for popliteal nerve blockade. *Anesth Analg*, 92, 2001, 215-7.
- Yuen EC, So YT. Sciatic neuropathy. *Neurol Clin*, 17, 1999, 617-31.